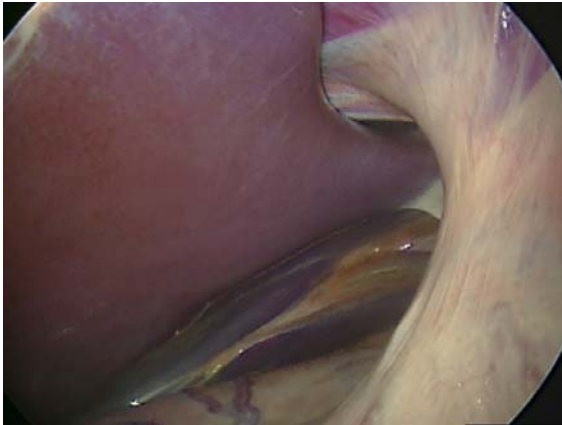

## Normal Laparoscopic Anatomy

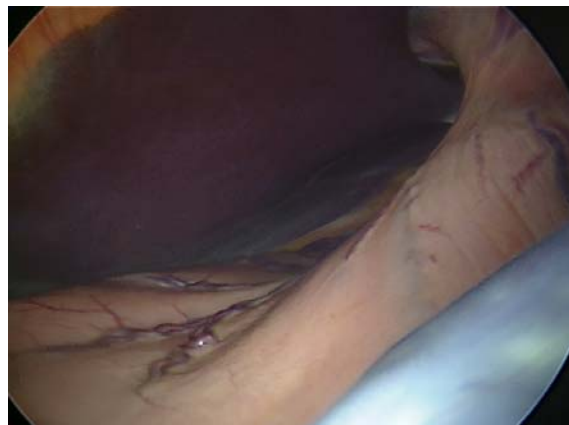The abdomen can be divided into two halves, a left and a right, to make it easier to describe. Our examination begins normally on the left hand side and then proceeds to the right.

### **Structures seen during standing laparoscopic examination**

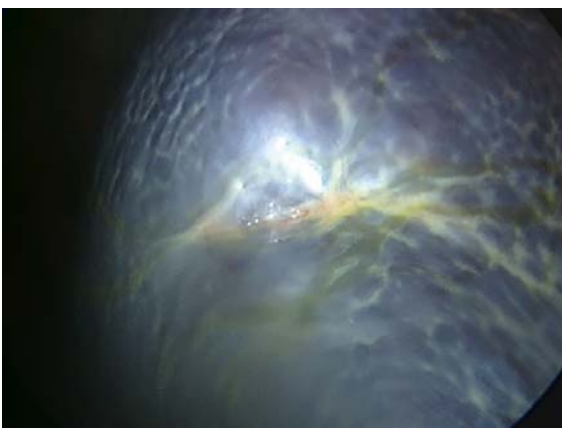
Left side of abdomen	Right side of abdomen
Diaphragm	Liver
Liver	Duodenum
Stomach	Pancreas
Spleen	Large colon
Left kidney	Caecum
Left side of male and female reproductive tracts	Right side of male and female reproductive tracts
Small colon	Right kidney
Bladder	Bladder
Small intestine	Small intestine
	Small colon
	Rectum



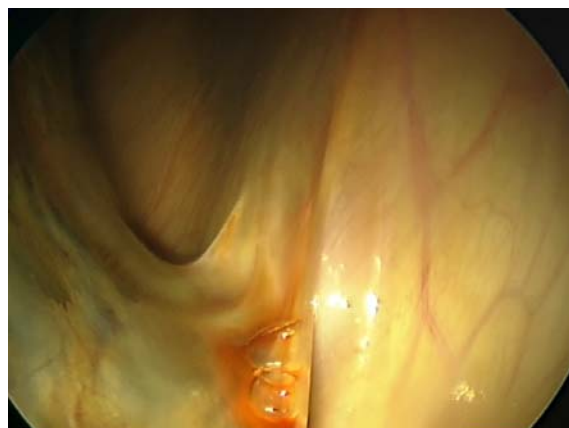Left lobe of liver



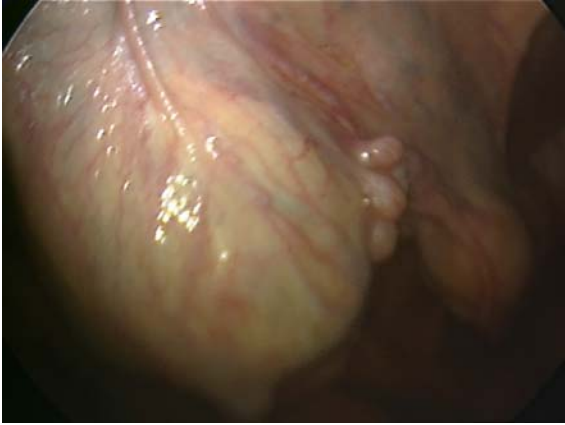Stomach



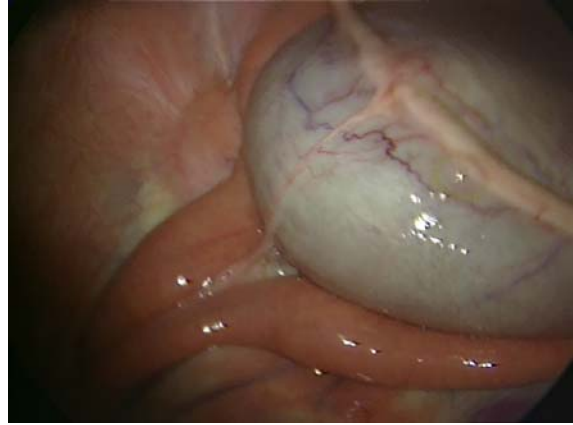
Spleen



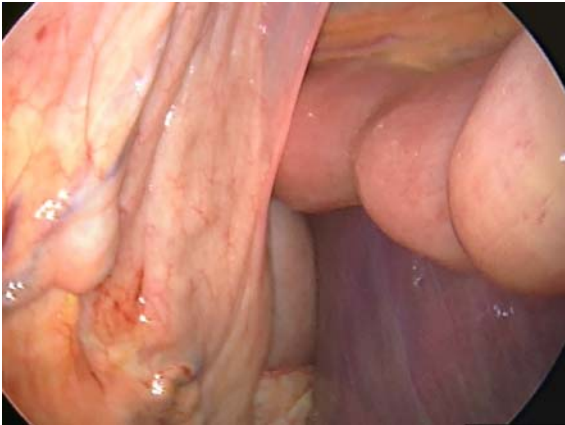
Nephrosplenic ligament



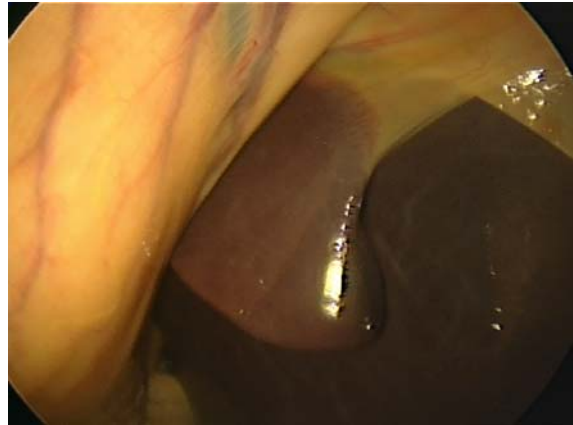
Ovary and uterus



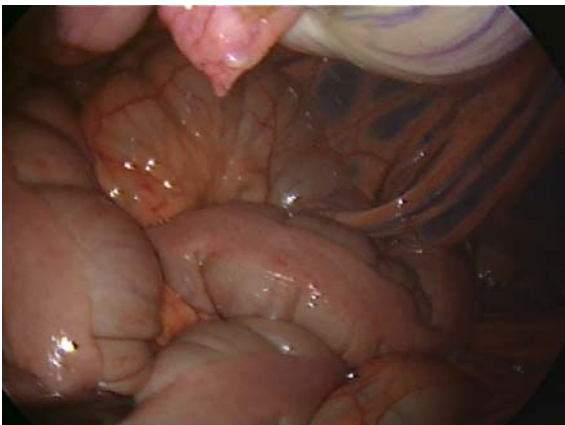Bladder



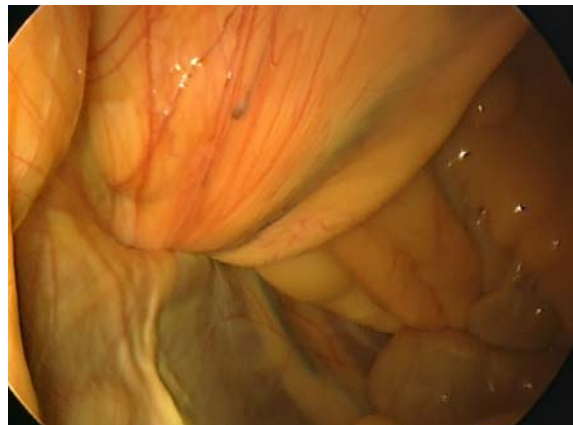Duodenum and caecal base



Right lobe of liver



Small colon



Right inguinal canal

Ascending duodenum